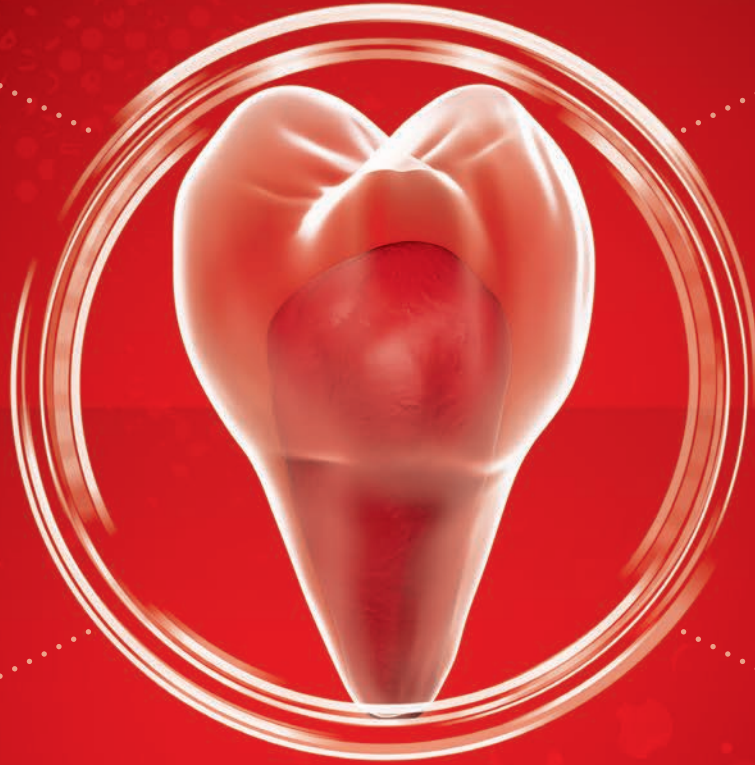



Paediatrics

**ACTIVE
BIOSILICATE
TECHNOLOGY**

BiodentineTM

Dentine Substitute



Biodentine™: the better standard for younger patients' teeth⁽⁵⁾

1

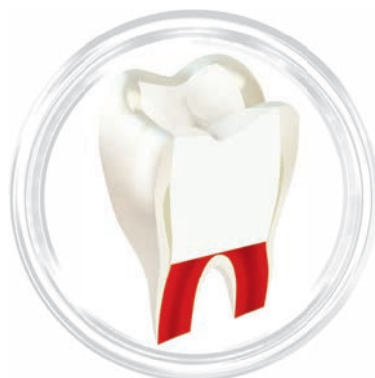Maintain pulp vitality

- Biodentine™ is bioactive and promotes the pulp's self healing capacity
- In indirect and direct pulp caps, in partial or total pulpotomies: Biodentine helps you save the pulp every time it's not inflamed
- Its bioactivity allows the apical closure of immature teeth
- Its high pH reduces the risk of bacterial proliferation.

2

Adapted to younger patients

- Biodentine™ is "bulk filled" into the cavity
- It can be left as a temporary restoration for up to 6 months
- The final restoration in the same session is possible, whether a direct composite or a crown
- No post-operative pain and no discolouration
- No need for extra bonding, no extra steps.

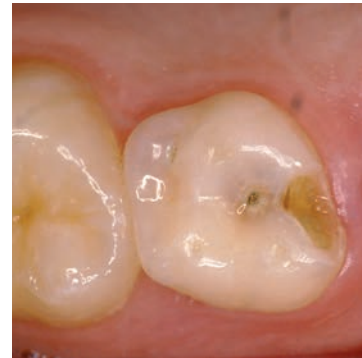

Final restoration placed within 6 months

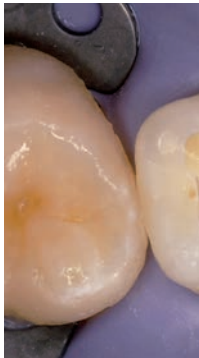Clinical cases

Pulpotomy

This includes pulpotomy in temporary teeth and partial pulpotomy in permanent teeth. Beside its bioactivity, Biodentine™ fast setting time allows immediate crown restoration. It also allows to make it directly intraorally functional without fear of material deterioration.



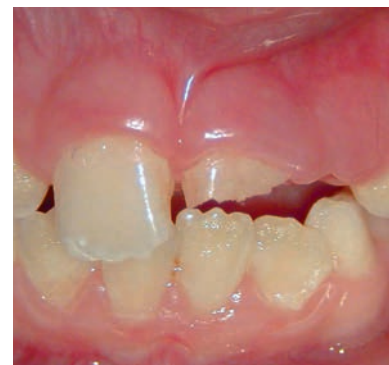Initial clinical view of #55 for a 8-year-old patient.



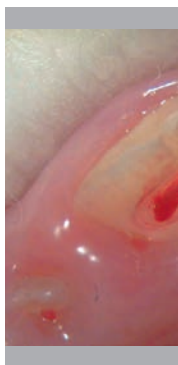Pulp exposure during caries curettage necessitating a cervical pulpotomy. Inflammatory, haemorrhagic

Traumatized teeth

Incisors are mostly concerned when it comes to crown fractures. Treatment of these complicated fractures in immature teeth is often a real challenge since the goal is to stimulate the pulp so that the apex can pursue its physiological maturity process. Biodentine™ shows dentine-like mechanical properties, triggers no tooth discoloration and has a short setting time (12 min). It is therefore the material of choice for fragilised immature teeth.



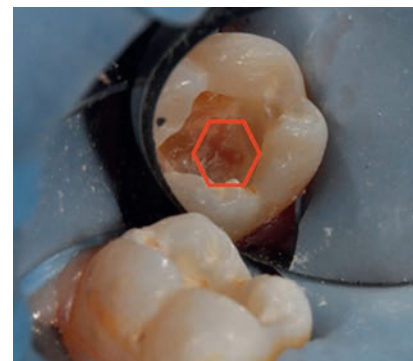Complicated crown fracture with reversible pulpitis of tooth #21.



Partial pulpotomy of tooth #21. Haemorrhage was

Deep caries treatment

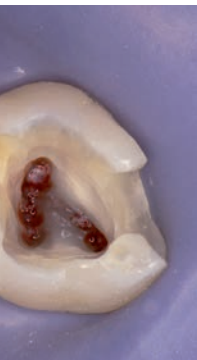After curettage of caries, the pulp may be seen by transparency or may be exposed. Biodentine™ is a restorative material that can directly be placed on the pulp and is evaluated as superior to MTA, CaOH and formocresol in numerous publications. It offers zero discoloration of teeth, provides an outstanding seal, is easy to handle, sets fast and is antibacterial. You can therefore “bulk fill” Biodentine™ without extra conditioning and bonding.



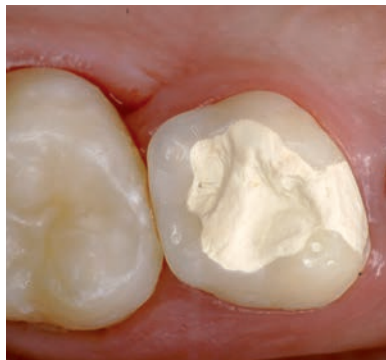7 year olds tooth #46 after caries removal, deep cavities in close proximity to the pulp.



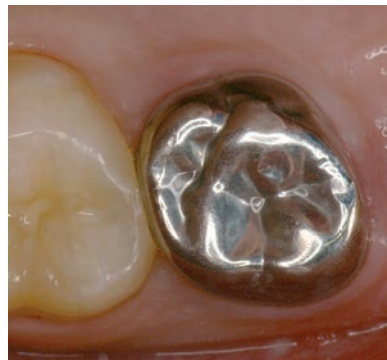Indirect capping of tooth #46 before and after



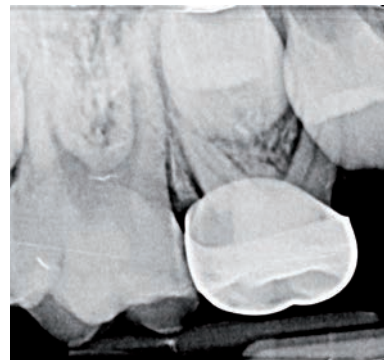the course of
essitates carrying out
(vital pulp, non-
stasis possible).



Bulk fill Biodentine™ from the pulp
chamber to the occlusal surface.

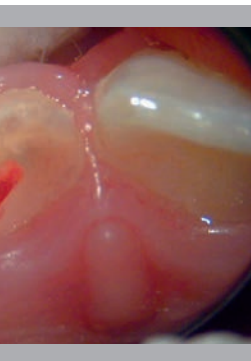

One month later, placement of a
paedodontic cap.

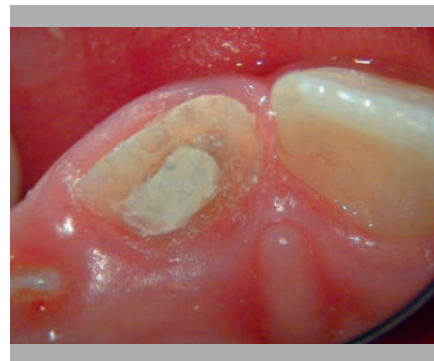

X-ray follow-up image at 3 months
showing the absence of any
periradicular lesion.

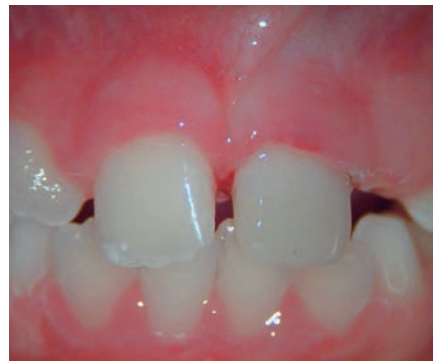Case courtesy of Dr. Lucile Goupy France



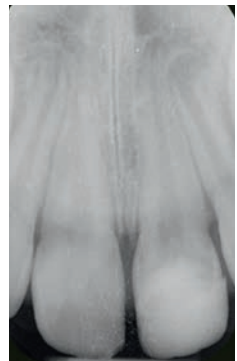
was carried out, then the
controlled.



Bulk fill Biodentine™ as a pulp capping
material and a temporary restoration.

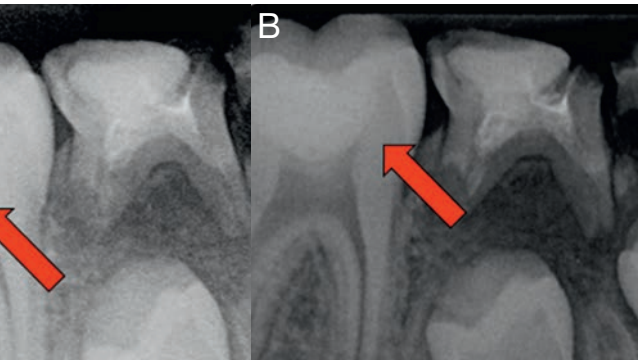


After one week, Biodentine™ had fully set
and had not washed out, the patient was
asymptomatic and final restoration was done
with composite.

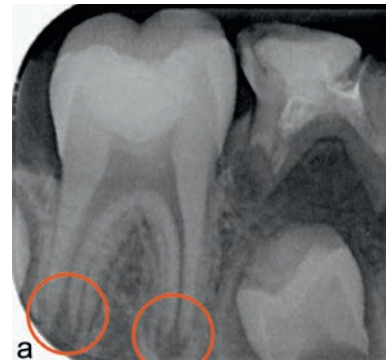

X-ray follow-up
image at 12 months
showing continued root
formation.

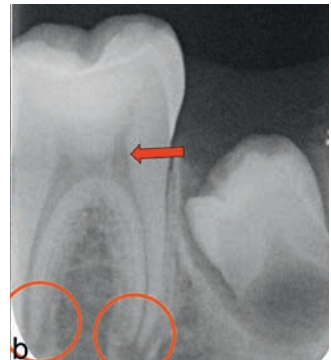Case courtesy of Dr. Athina Bakopoulou, Aristotle University of
Thessaloniki, Greece



g with Biodentine™, Figure A and B show the radiographic image
er treatment.



Radiography after treatment.



X-ray follow-up image at
12-months, showing the
continued formation of radicular
apices.

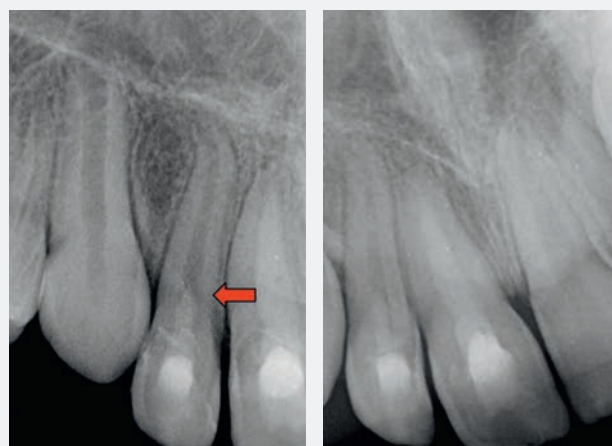Case courtesy of Prof. Luc Martens and Dr. Rita Cauwels

For younger patients, historical treatments are not always pulp friendly and show many drawbacks. With Biodentine™, you give children the better care they deserve for their dental treatments, with an easy and fast procedure for you.

Technical Insights

Higher biocompatibility and bioactivity for pediatric indications

- High biocompatibility assessed and evidenced through 500 scientific publications
- Highest amount of calcium and hydroxide ions released upon setting⁽¹⁾
- Induces thick dentine bridge formation⁽²⁾ thanks to largest calcium surface concentration compared to similar dental materials⁽³⁾
- Shows both osteogenic and angiogenic properties to promote pulp and tissues healing⁽⁴⁾
- Calcium silicate based materials show better clinical and radiographic results than Formocresol⁽⁵⁾
- Allows the tooth to grow normally



Immediate post-op X-ray after Biodentine placement. The open apex is clearly visible.

The 9-month follow-up Xray shows the apical closure.

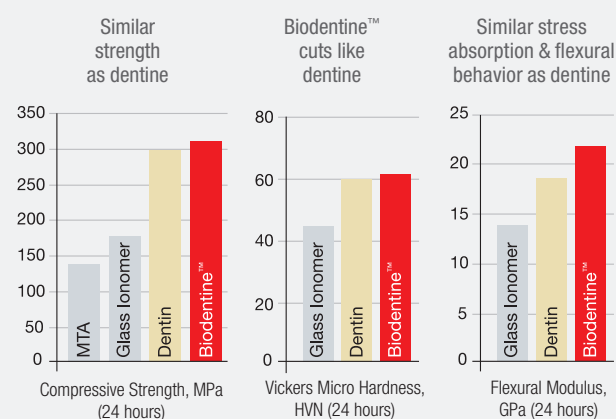
Courtesy Prof. L. Martens & Prof. R. Cauwels, UZ Ghent, Belgium

Bulk fill placement for a strong restoration

- Similar mechanical properties as dentine allowing durable bulk fill procedure
- Fast growing mechanical strength allowing solid restoration as soon as Biodentine™ is set
- Shows no depth of cure limitation thanks to its biosilicate chemistry

Product properties designed for paediatric dentistry

- Short setting time of 12 mins allowing rapid placement of a stainless steel crown when necessary
- No post-operative pain⁽⁶⁾
- No tooth discoloration⁽⁷⁾
- Antimicrobial properties thanks to alkaline ph(=12)⁽⁸⁾



Source Biodentine™ Scientific File

Total handling time

12 min	
Mixing & placement time	Setting time in mouth
6 min	6 min

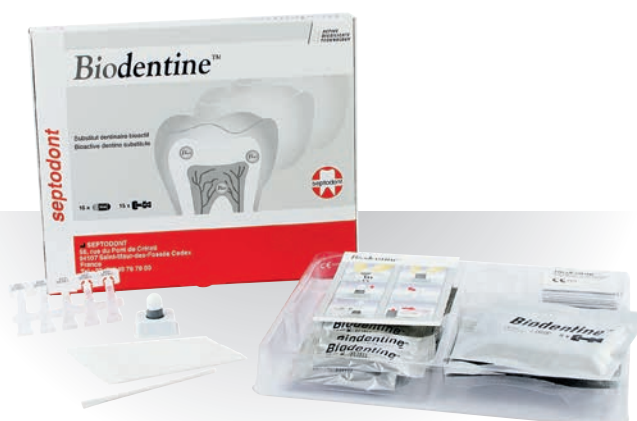

Authors	Title	Journal	Year	Ref.
Kurun Aksoy M, Tulga Oz F, Orhan K.	Evaluation of calcium (Ca ²⁺) and hydroxide (OH ⁻) ion diffusion rates of indirect pulp capping materials	International Journal of Artificial Organs	2017	1
Gong V, França R.	Nanoscale chemical surface characterization of four different types of dental pulp-capping materials	Journal of Dentistry	2017	3
Costa F, Sousa Gomes P, Fernandes MH.	Osteogenic and Angiogenic Response to Calcium Silicate-based Endodontic Sealers	Journal of Endodontics	2016	4
El Meligy OA, Allazzam S, Alamoudi NM.	Comparison between Biodentine™ and formocresol for pulpotomy of primary teeth: A randomized clinical trial	Quintessence	2016	
Grewal N, Salhan R, Kaur N, Patel HB.	Comparative evaluation of calcium silicate- based dentin substitute (Biodentine™) and calcium hydroxide (pulpdent) in the formation of reactive dentin bridge in regenerative pulpotomy of vital primary teeth: Triple blind, randomized clinical trial	Contemporary Clinical Dentistry	2016	
Özyürek T, Demiryürek EÖ.	Comparison of the antimicrobial activity of direct pulp-capping materials: Mineral trioxide aggregate-Angelus and Biodentine™	Journal of Conservative Dentistry	2016	8
Martens L, Rajasekharan S, Cauwels R.	Endodontic treatment of trauma-induced necrotic immature teeth using a tricalcium silicate-based bioactive cement. A report of 3 cases with 24-month follow-up.	European Journal of Pediatric Dentistry	2016	
Evren OK, Altunsoy M, Tanriver M, Capar ID, Kalkan A, Gok T.	Fracture resistance of simulated immature teeth after apexification with calcium silicate-based materials	European Journal of Pediatric Dentistry	2016	
Nowicka A, Wilk G, Lipski M, Koleccki J, Buczkowska-Radlińska J.	Tomographic Evaluation of Reparative Dentin Formation after Direct Pulp Capping with Ca(OH) ₂ , MTA, Biodentine™, and Dentin Bonding System in Human Teeth	Journal of Endodontics	2015	2
Camilleri J.	Staining Potential of Neo MTA Plus, MTA Plus, and Biodentine™ Used for Pulpotomy Procedures	Journal of Endodontics	2015	7
Koubi G, Colon P, Franquin JC, Hartmann A, Richard G, Faure MO, Lambert G.	Clinical evaluation of the performance and safety of a new dentin substitute, Biodentine™, in the restoration of posterior teeth - a prospective study	Clinical Oral Investigation	2012	6
Peng L1, Ye L, Tan H, Zhou X.	Evaluation of the formocresol versus mineral trioxide aggregate primary molar pulpotomy: a meta-analysis	Oral Surgery, Oral Medicine, Oral Pathology, Oral Radiology	2006	5

Presentation

Available in:

- Box of 15 capsules and 15 single-dose containers



Septodont - Units R & S - Orchard Business Centre - St Barnabas Close - Maidstone - Kent - ME16 0JZ

Tel: +44 (0)1622 695520

Fax: +44 (0)1622 695521

Please visit our website for more information:

www.septodont.co.uk

